

CASE OF THE QUARTER



Dr. Bill Robbins

Patient presented with infection tooth #9. (X-rays and figs. 1 & 2)

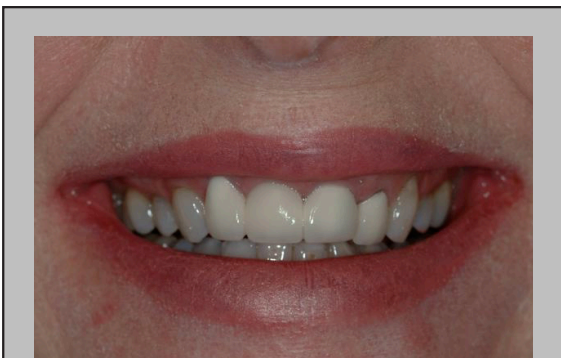
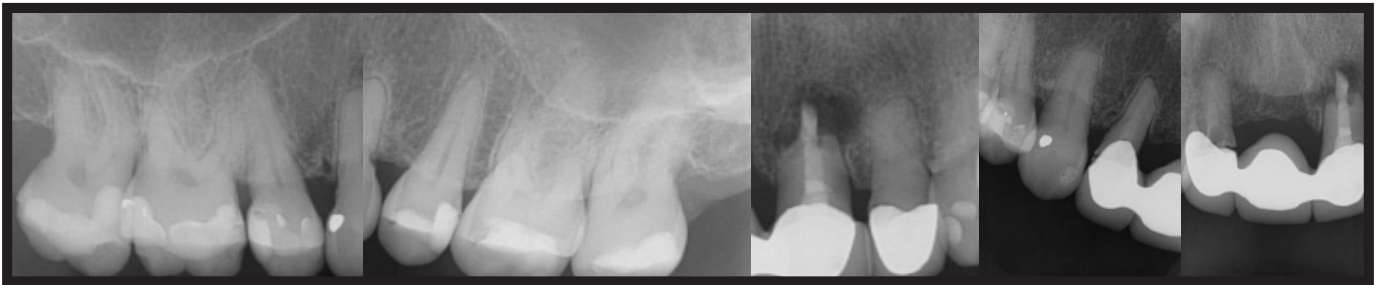

Fig. 1

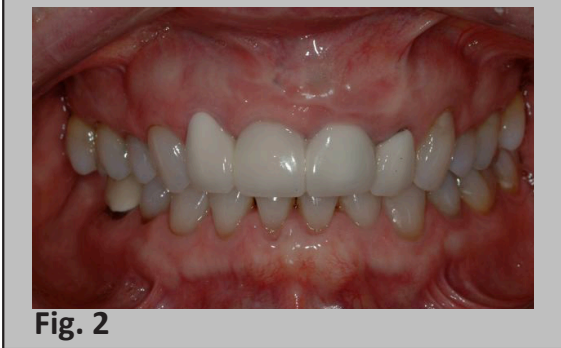


Fig. 2

I removed bridge #7-9 and crown #10 and amputated the teeth at the gum-line. I did a gingivectomy #4,6,13 and prepared #4,6,11,13 for crowns and placed a chair-side fabricated provisional bridge #4-6-11-13. I also made an impression for a lab fabricated provisional bridge #4-6-11-13 since it would be in place for several months. The laboratory fabricated provisional bridge was inserted (fig 3),

I then referred the patient to Dr. Rindler and he extracted #7,9,10, did connective tissue grafts #8,9 and placed implants #8,9. He also did functional crown lengthening surgery #4,6,13. After implants integrated, we placed a screw retained provisional, but it was long and unaesthetic and had screw access holes through facial (fig 4).

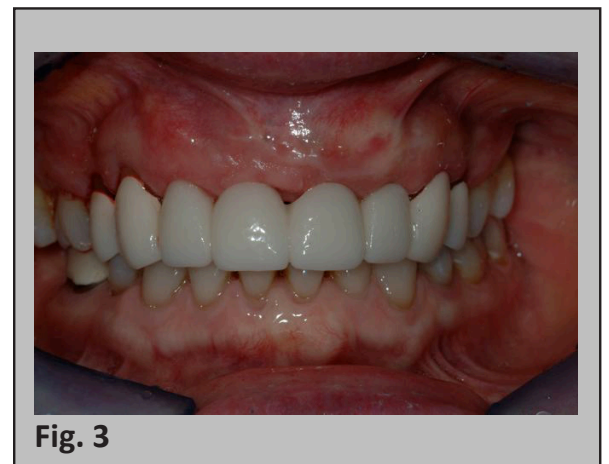

Fig. 3

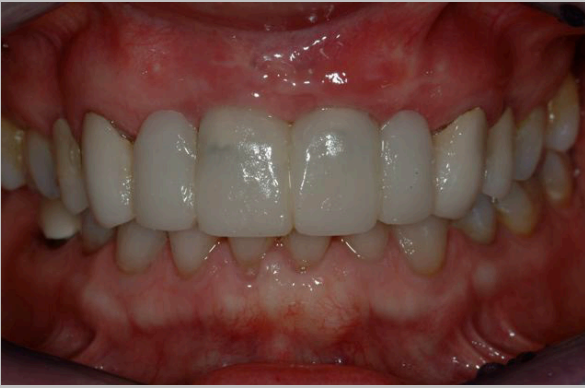

Fig. 4

So we made impression for JKAD custom abutments and laboratory-milled screw retained provisional with pink gingiva, which was very esthetic (figs 5,6,7).

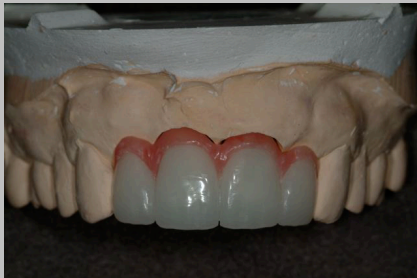

Fig.5

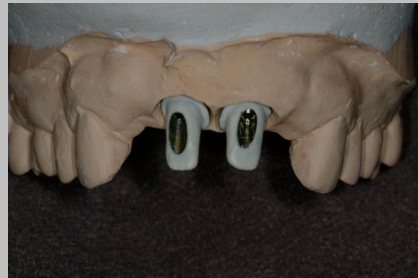

Fig. 6

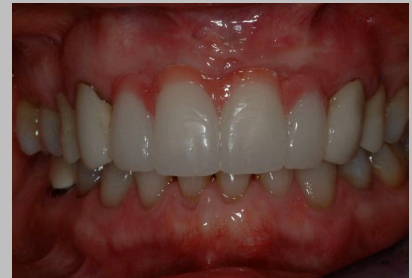

Fig. 7

Ultimately we placed crowns #3,4,6,11,13,14 and the bridge from #7-10. (figs 8,9)

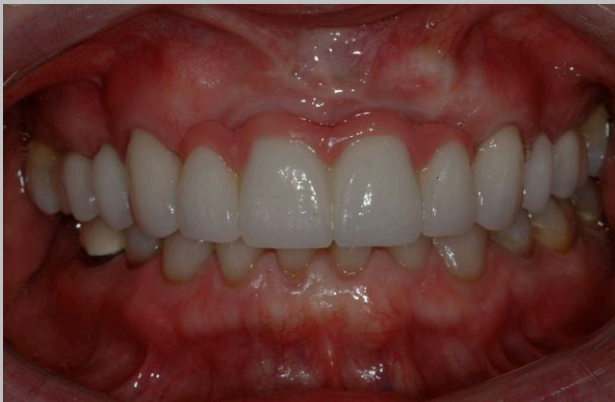

Fig. 8

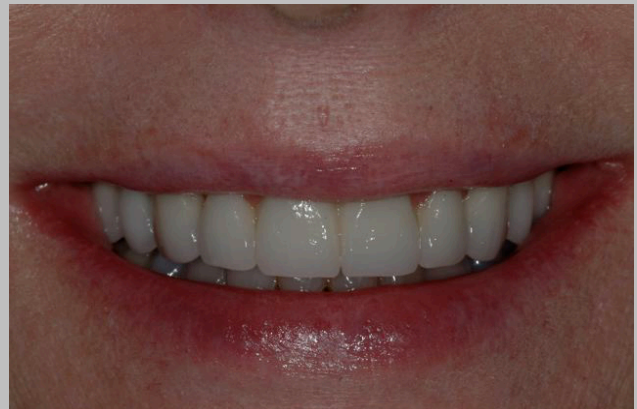

Fig. 9



J. William Robbins, D.D.S., M.A.
1202 East Sonterra Blvd.
Suite 402 San Antonio, Texas 78258
Phone: (210) 341-4409
E-mail: robbinsdds@aol.com
Website: www.robbinsdds.com

J. William Robbins, D.D.S., M.A., maintains a full-time private practice and is Clinical Professor in the Department of Comprehensive Dentistry at the University of Texas Health Science Center at San Antonio Dental School. He graduated from the University of Tennessee Dental School in 1973. He completed a rotating internship at the Veterans Administration Hospital in Leavenworth, Kansas and a 2-year General Practice Residency at the V.A. Hospital in San Diego, California. Dr. Robbins has published over 80 articles, abstracts, and chapters on a wide range of dental subjects and has lectured in the United States, Canada, Mexico, South America, Europe, Middle East and Africa. He coauthored a textbook, Fundamentals of Operative Dentistry – A Contemporary Approach, which is published by Quintessence, and is in its 4rd edition. He has won several awards including the Presidential Teaching Award at the University Of Texas Health Science Center, the 2002 Texas Dentist of the Year Award, the 2003 Honorary Thaddeus V. Weclaw Fellowship Award from the Academy of General Dentistry, the 2010 Saul Schluger Award given by the Seattle Study Club and the Southwest Academy of Restorative Dentistry 2015 President's Award. He is a diplomat of the American Board of General Dentistry. He is past president of the American Board of General Dentistry, the Academy of Operative Dentistry, the Southwest Academy of Restorative Dentistry, and is immediate past president of the American Academy of Restorative Dentistry. He is a member of several organizations including: The American College of Dentists, the International College of Dentists, The American Dental Association, The American Academy of Restorative Dentistry, The Southwest Academy of Restorative Dentistry, The Academy of General Dentistry, and The Academy of Operative Dentistry.